



In the early evolution of porcelain veneers, temporization or provisionalization was difficult to accomplish, since easy and predictable methods for fabrication of temporaries had not been developed for this type of esthetic treatment. Early literature omitted the temporization step altogether<sup>1</sup> or stated that “generally, sufficient enamel thickness remains to eliminate the need for temporary restorations”<sup>2</sup> or that “temporization is seldom necessary if the preparation has been kept totally in enamel.”<sup>3</sup> This early literature discussed minimal intra-enamel labial porcelain veneer preparations that did not address the complications of severe wear, diastema closure, rotations and re-alignment, color change, or more complicated modifications of the dentition due to esthetic requirements. Of course this minimalist approach was driven by the fact that enamel bonding was predictable and bonding to dentin unpredictable. This approach of not temporizing the veneer preparations, often led to the perception by the patient, on cementation of the veneers, that the finished veneers were too large or thick, since the patient had accommodated to the smaller labio-lingual dimension of the teeth. This fact, which may lead to loss of confidence by the patient in the final result or in the dentist, is by itself one of many good reasons to temporize.

## provisionals: *Alternative Methodologies*

By Len Boksman DDS, BSc, FADI, FICD  
Gary Alex, DMD • Robert C. Margeas DDS, FAGD

When treating dentitions that require a major change in shape, contour, length, or position (Fig. 1),

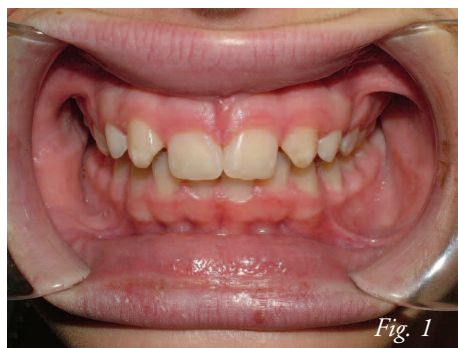

Fig. 1

Figure 1: Pre-operative photograph of patient with missing laterals and cuspids moved into the lateral position.

“The diagnostic wax-up can be the single most useful tool for helping to determine not only how the patient’s mouth should look and function, but also for communication with the patient and implementation of the treatment”<sup>4</sup> (Fig. 2).

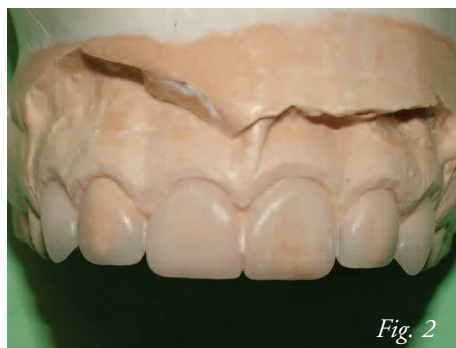

Fig. 2

Figure 2: Diagnostic esthetic wax-up of the same patient showing the drastic improvement possible with porcelain veneers.

The transfer of this wax-up as a positive reproduction intra-orally allows the patient to more accurately visualize the anticipated final result<sup>5,6</sup> (Fig. 3).

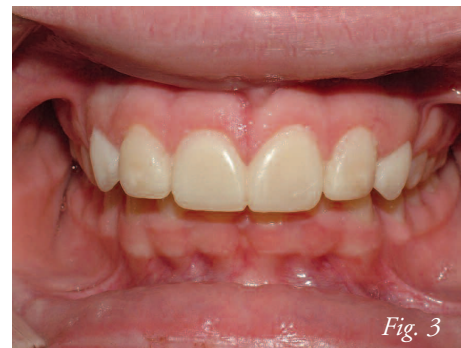

Fig. 3

Figure 3: Diagnostic wax-up transferred to the patient for evaluation of esthetics, form, function and effective communication with the patient.

For the dentist this intraoral mock-up can be used to assess function, phonetics, esthetics, and can be used as a matrix for depth cuts, driving the exact reduction necessary for minimal loss and preservation of tooth structure.<sup>7</sup>

*continued on page 62*

This article will look at three alternative methodologies for fabricating temporary restorations for porcelain veneers. It is up to the practitioner to evaluate which system works best in his/her hands.

## Direct Light Cured Temporary Composite

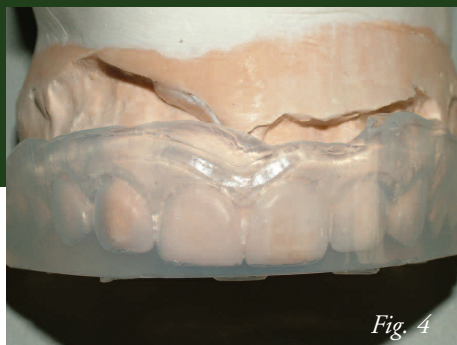

Fig. 4

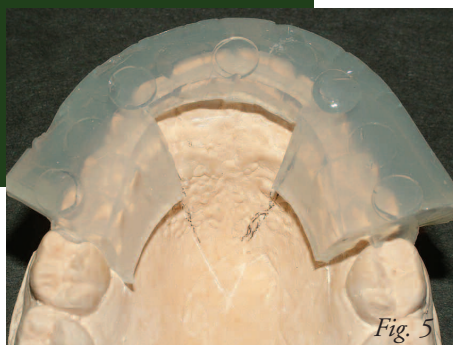

Fig. 5

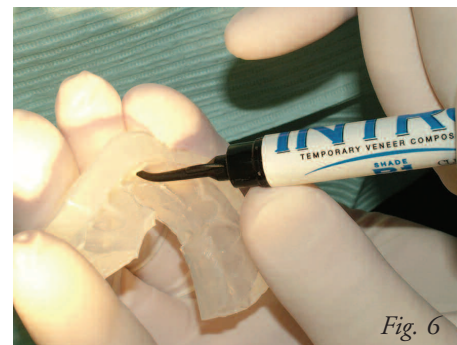

Fig. 6

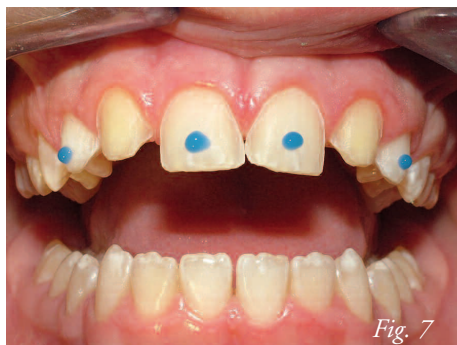

Fig. 7

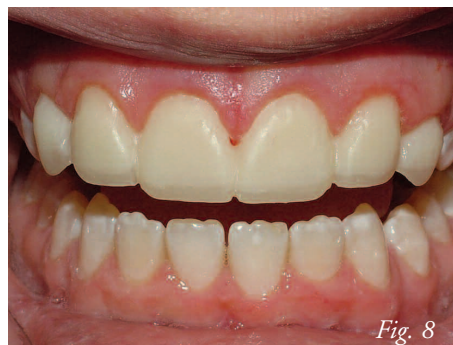

Fig. 8

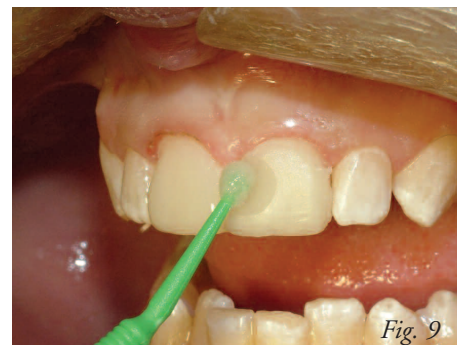

Fig. 9

Figure 4: Affinity Crystal (Clinician's Choice), a water clear silicone impression/matrix material is used in a disposable tray without adhesive over the diagnostic wax-up, to create a matrix for temporization of the preparations. Affinity Crystal silicone impression over the diagnostic wax-up clearly shows the underlying model. This facilitates precise intraoral placement

Figure 5: The Affinity Crystal is removed from the tray and is cut back on the lingual, 1 mm short of the linguo-incisal edge cavo-surface margin of the anticipated veneer preparation to allow for access to remove the excess lingual temporary material and minimize post-insertion finishing.

Figure 6: Incisal Intro Light Cured Temporary Composite (Clinician's Choice) is placed minimally first in the incisal 1/2-1 mm, followed by the appropriate body color of Intro composite, which is placed on the labial surface of the clear silicone matrix.

Figure 7: Every second prepared tooth is spot etched (Ultra-Etch Ultradent) in the center of the tooth and D/E Bond Resin

(Bisco) is applied to the enamel to seal the surface and create a bond in the etched areas only.

Figure 8: The Affinity Crystal matrix with the Intro composite is carried to the teeth, adapted well to the gingival tissues on the labial to minimize the thickness of flash and the lingual excess is removed. The temporary composite resin is then light cured just enough (8-10 seconds) so that when the matrix is removed, the excess flash can then be carved easily with a 12 B Bard Parker Blade.<sup>8</sup> If the Intro tears when using the scalpel, light cure the temporary composite for a few more seconds.

Figure 9: A glaze (Tempglaze, Clinician's Choice) can be placed and cured with a full spectrum curing light to add a life-like luster to the surface and to eliminate the polishing step. It is critical to remember that many LED curing lights do not cure materials that have proprietary initiators and materials that contain PPD (phenyl propane dione).



## Rapid Simplified Veneer Provisional System

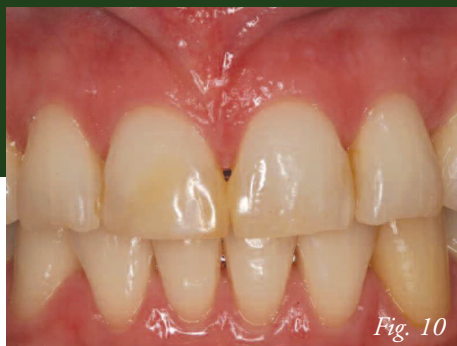

Fig. 10

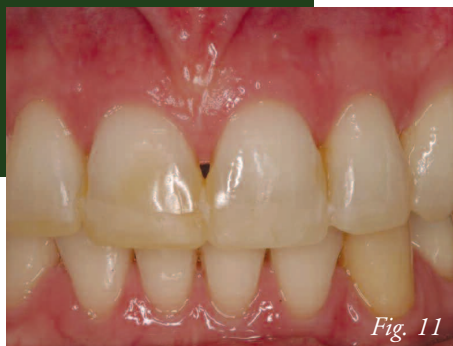

Fig. 11

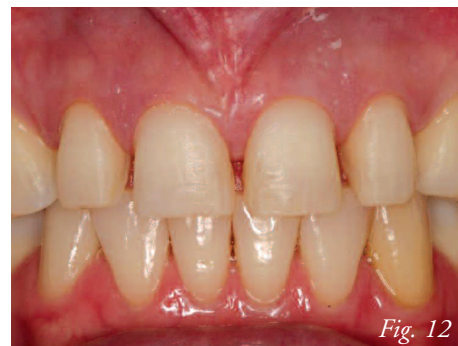

Fig. 12

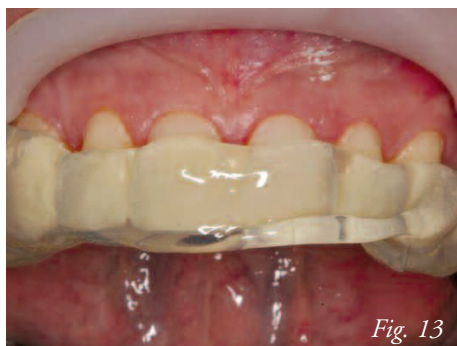

Fig. 13

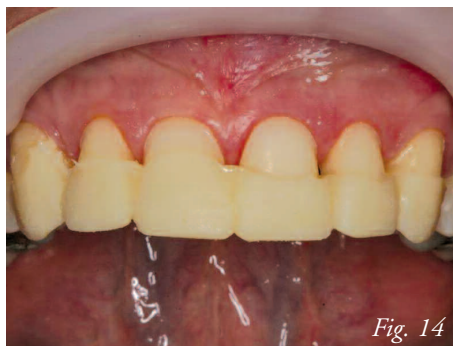

Fig. 14

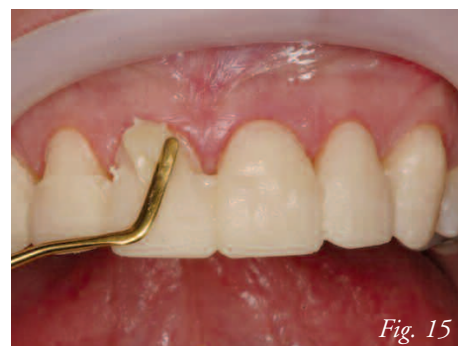

Fig. 15

Figure 10: Anterior dentition of patient with incisal wear, shortening of the cuspid and lateral protrusive wear facet on the lateral incisor.

Figure 11: Composite mock-up intra-orally to lengthen the anteriors, thereby assessing phonetics, function and esthetics.

### Interim Step:

After verification of function, phonetics and esthetics, an impression was taken and a stone model was fabricated of the final desired result. A clear polyvinyl siloxane matrix material (RSVP Cosmedent, Affinity Crystal) is placed on the model with a clear tray.<sup>9</sup> The tray is cut just incisal to the papilla so there is access for removal. The RSVP matrix material is then modified or trimmed on the model, on the labial aspect with a #15 Bard Parker scalpel (Becton, Dickson, and Company) to remove the cervical one third of the matrix on those teeth to be restored.

Figure 12: Minimally invasive porcelain veneer preparations are completed on the anteriors with most of the preparations maintained in enamel.

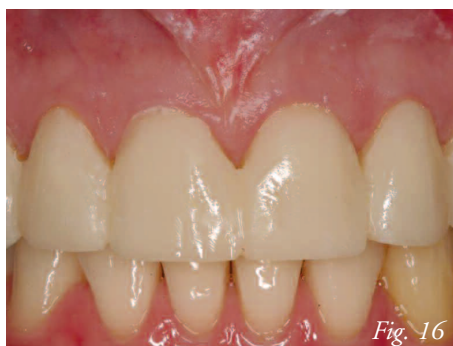

Fig. 16

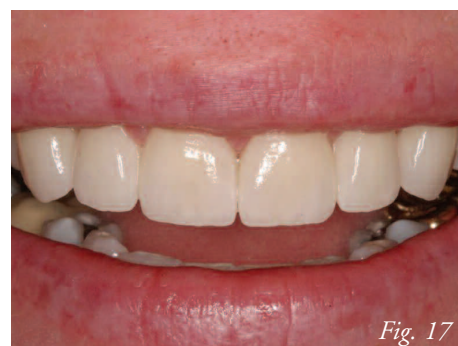

Fig. 17

Figure 13: If there are less than 4 teeth spot etch (UltraEtch) and seal with an unfilled resin (D/E Bond Resin). The silicone matrix filled 1/2-3/4 with RSVP incisal composite is carried to the mouth. Excess material is removed from the gingival area and after light curing for 10 seconds, the matrix is removed (Fig. 14).

Figure 14: The matrix has been removed showing the incisal 1/2 of the teeth built to length and contour.

Figure 15: Next the gingival portion of the temporary restorations is created and sculpted "free-hand" with RSVP cervical

composite (Cosmedent) and then light cured. This no slump material allows adaptation to the margins, minimizing the need for finishing (Fig. 15).<sup>10</sup>

Figure 16: The final luster can be created with discs (Top Finisher System Cosmedent) or a surface glaze (Biscover LV Bisco). Photograph of the temporaries on the day of final cementation showing the maintenance of high luster and good cosmetics.

Figure 17: Porcelain veneers on the day of insertion and cementation re-creating cuspid and anterior guidance.

## Provisionals Using Self-cure BIS-acryl Based Resins

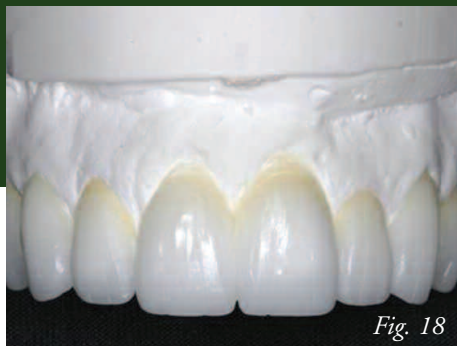

Fig. 18

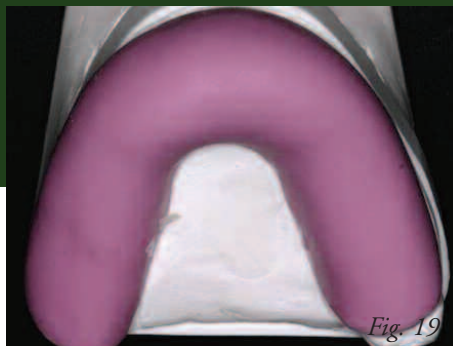


Fig. 19

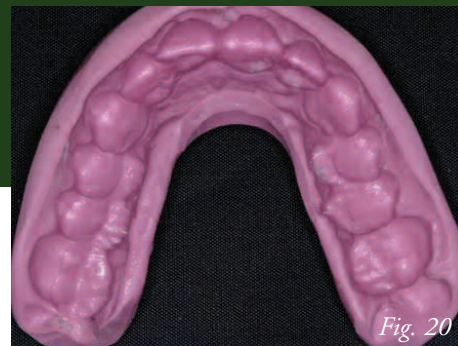

Fig. 20

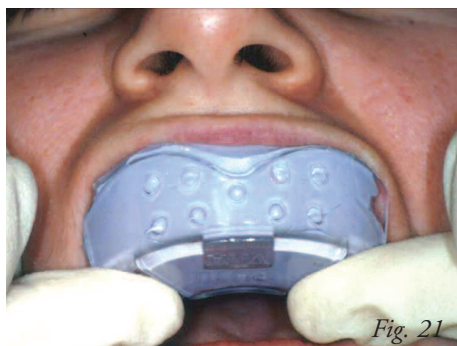

Fig. 21

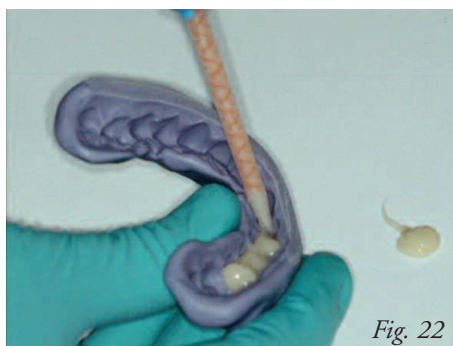


Fig. 22

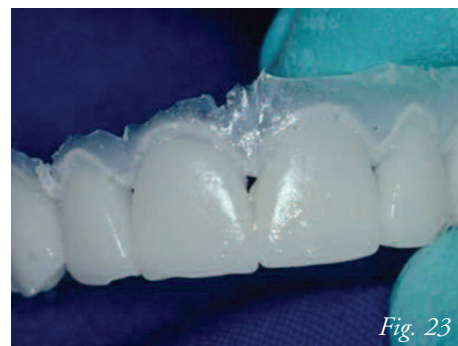

Fig. 23

One common method for the provisionalization of multiple veneer preparations is the use of BIS-acryl based self-cure resins (Temptation Clinician's Choice, Luxatemp Plus Zenith, Integrity Dentsply/Caulk, ProTemp 3 Garant 3M ESPE) used in conjunction with a prefabricated matrix. The matrix is typically fabricated from a diagnostic wax-up or direct impression of the patient's own teeth. When using the patient's existing dentition a stiff alginate or a more stable, accurate, and re-usable polyvinyl siloxane impression material can be used to directly impress the teeth prior to preparation. As discussed above, the dentist may first choose to modify the teeth by shaping or adding composite so that the provisionals duplicate what the dentist "thinks" the case should look like in its final form. When significant form, length, or positional changes are required, it is advantageous to work from a diagnostic wax-up. A hand-mixed putty type material such as Affinity Putty (Clinician's Choice) or Sil-Tech Putty (Ivoclar Vivadent) (Fig. 18, 19, 20) can be used.

Figure 18: Esthetic wax-up of the patient showing recontouring and re-alignment of the anterior 10 teeth.

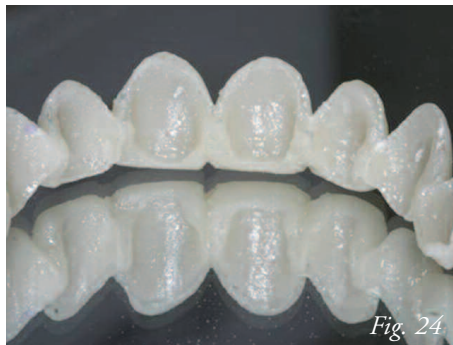

Fig. 24

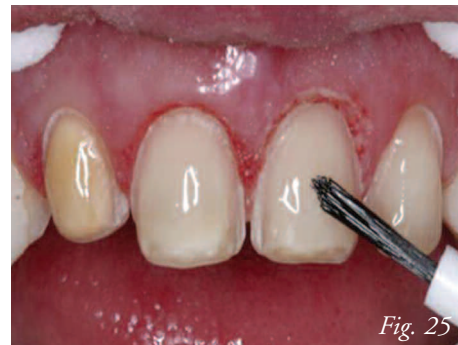

Fig. 25

Figure 19: Putty polyvinyl siloxane material is adapted over the esthetic wax-up to minimally cover the gingival tissues and give rest position on un-prepared teeth.

Figure 20: The putty matrix is trimmed. Note the adaptation of the polyvinyl siloxane to the interproximal and tissue areas, which is difficult to duplicate in an alginate impression.

Figure 21: If the patient's teeth do not require an esthetic wax-up, or the mock-up is done in the mouth, a quick setting polyvinyl siloxane impression can be taken in a disposable tray.

Figure 22: The self-cure BIS-acryl composite resin is injected into the putty matrix

with the tip left in to minimize the formation of air bubbles and carried to the mouth and seated firmly.

Figure 23: The set BIS-acryl temporary is carefully removed from the mouth so it can be trimmed, finished and polished without compromising the prepared margins of the veneers.

Figure 24: The finished veneer temporary is sandblasted on the lingual to improve retention, unfilled resin is placed and covered with a flowable composite. The provisionals are then temporarily bonded to the preparations using the "spot bonding" technique.

Figure 25: The teeth are "spot" etched, washed and the surface covered with an unfilled resin to bond and seal the preparations.



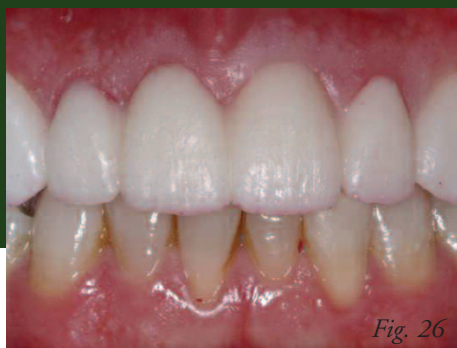

Fig. 26

Figure 26: The Bis-acryl temporaries are bonded into place with light cure, after removal of all excess flowable composite resin.

Never place a dentin-bonding agent on the teeth prior to seating the provisionals as this would create too strong a bond and removal may be extremely difficult. It would also necessitate re-freshing the surface at the final cementation appointment to create a clean bonding site.

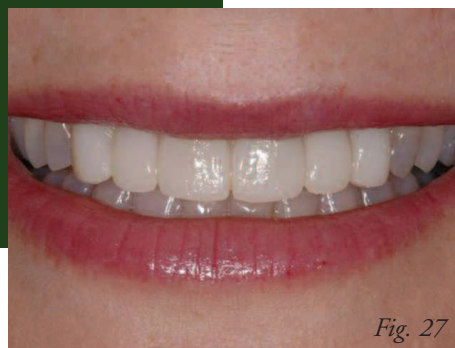

Fig. 27

Figure 27: Evaluation of the finished temporaries for esthetics, form and function. These temporaries should give the patient an exact duplication of what the final porcelain veneers will look like. If adjustments are required this information can be conveyed to the laboratory as a guide to final restoration design. At the cementation appointment the temporaries are easily removed and the cementation process can begin.

Figures 1, 2, 3, 4, 7, 8 are used with permission of Oral Health. Previously published Oral Health 2006; April: 58-66



**Dr. Leendert (Len) Boksman** earned his DDS degree in 1972 from the University of Western Ontario. He is a fellow of the Academy of Dentistry International and the International College of Dentists. He has memberships in the Canadian Academies of Cosmetic as well as Esthetic Dentistry.

Dr. Boksman has been published in over 70 refereed articles, chapters in dental texts and is an international lecturer on Clinical Restorative Dentistry. Dr. Boksman currently holds a part time paid position as Director of Clinical affairs for Clinical Research Dental Supplies, distributor for Clinicians Choice.



**Dr. Gary Alex** attended Penn State University on an athletic scholarship where he graduated with a degree in Biology in 1977. He then took advanced level graduate courses in chemistry and biology before working at Jefferson Hospital in Philadelphia. He attended Tufts University Dental School where he earned his DMD in 1981. He has taken thousands of

hours of continuing dental education over the last 26 years with an emphasis on occlusion, adhesion, comprehensive dentistry, materials, and esthetics



**Dr. Robert Margeas** serves as Adjunct Professor in the Department of Operative Dentistry at the University of Iowa. He is a clinical instructor at the Center for Excellence, Chicago, IL. Dr. Margeas is board certified by the American Board of Operative Dentistry and is a Fellow of the Academy of General Dentistry (AGD). He maintains a private practice

devoted to esthetic dentistry in Des Moines, IA.

#### Bibliography:

1. Boksman L, Jordan RE, Suzuki M, Galil KA, Burgoyne AR. Etched Porcelain Labial Veneers. *Ont Dent*. 1985 Jan; 62(1):11-19
2. McConnell RJ, Boksman L, Gnatton DR. Etched Porcelain Veneers. *Rest Dent* 1986 Nov; 2(6): 124-131
3. Boksman L. *Customized Laminate Veneers: Porcelain and Composite Clinical Dentistry*, James Clark, Harpers and Row Publishers, Philadelphia 1986 29A; 1-20
4. Waldman C. *The Diagnostic Wax-up: The Key to Success*. *JCDA* 2005 Feb; 71(2):124-5
5. Priest G. Assessing aesthetic expectations with provisional veneers. *Dent Today* 2005 Feb;24(2): 80, 82-3
6. Mizrahi B. Visualization before finalization; A predictable procedure for porcelain laminate veneers *Pract Proced Aesthet Dent* 2005;17(8):513-518
7. Magne P, Belser UC. Novel porcelain laminate preparation approach driven by a diagnostic mock-up. *J Esthet Restor Dent* 2004;16(1): discussion 17-8
8. Boksman L, Carson B. Porcelain Veneer Restoration of Canine Lateralization in Congenitally Missing Lateral Incisors: An Aesthetic Challenge. *Oral Health* 2006 April;58-67
9. Margeas RC, Nixon RL. RSVP (Rapid Simplified Veneer Provisional System) *Cont Esth and Rest Dent* 2001 Feb; 1-3
10. Phelan S. Precise and Predictable Provisional Veneers. *JCDA* 2004 Oct;70(9): 639-642